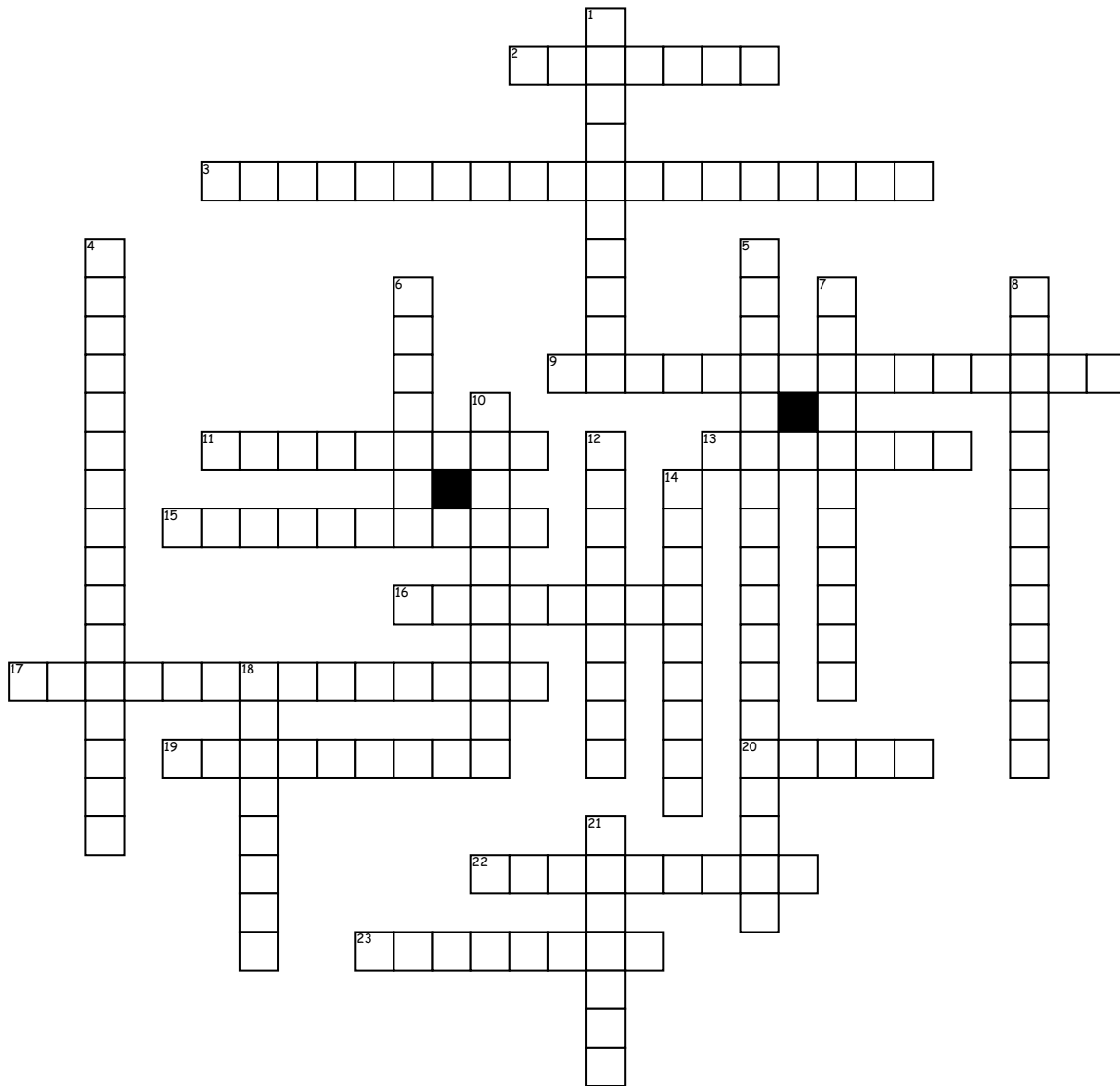


# Upper Arm & Shoulder



## Across

2. Opposite of extension  
 3. the head of the upper arm bone is forced out of the shoulder socket  
 9. Its posterolateral of the lesser tubercle  
 11. One of the two cartilage parts at the end of the humerus  
 13. Named after a Greek capital letter  
 15. prime mover of elbow flexion  
 16. Also known as the collarbone  
 17. responsible for extension of the elbow joint

## 19. Palms down

20. includes landmarks such as the olecranon, the elbow pit, the lateral and medial epicondyles

22. Away from midline

23. A groove at the lower end of humerus

## Down

1. adduct the humerus  
 4. Flexes and adducts the arm at the glenohumeral joint  
 5. happens when your elbow joint is bent beyond its normal range of motion  
 6. Also known as the shoulder blade

7. a group of muscles and tendons that act to stabilize the shoulder

8. it supinates the forearm

10. under pronation

12. Towards midline

14. Opposite of flexion

18. Its made up of the clavicle, scapula and humerus

21. Located between the elbow joint and shoulder