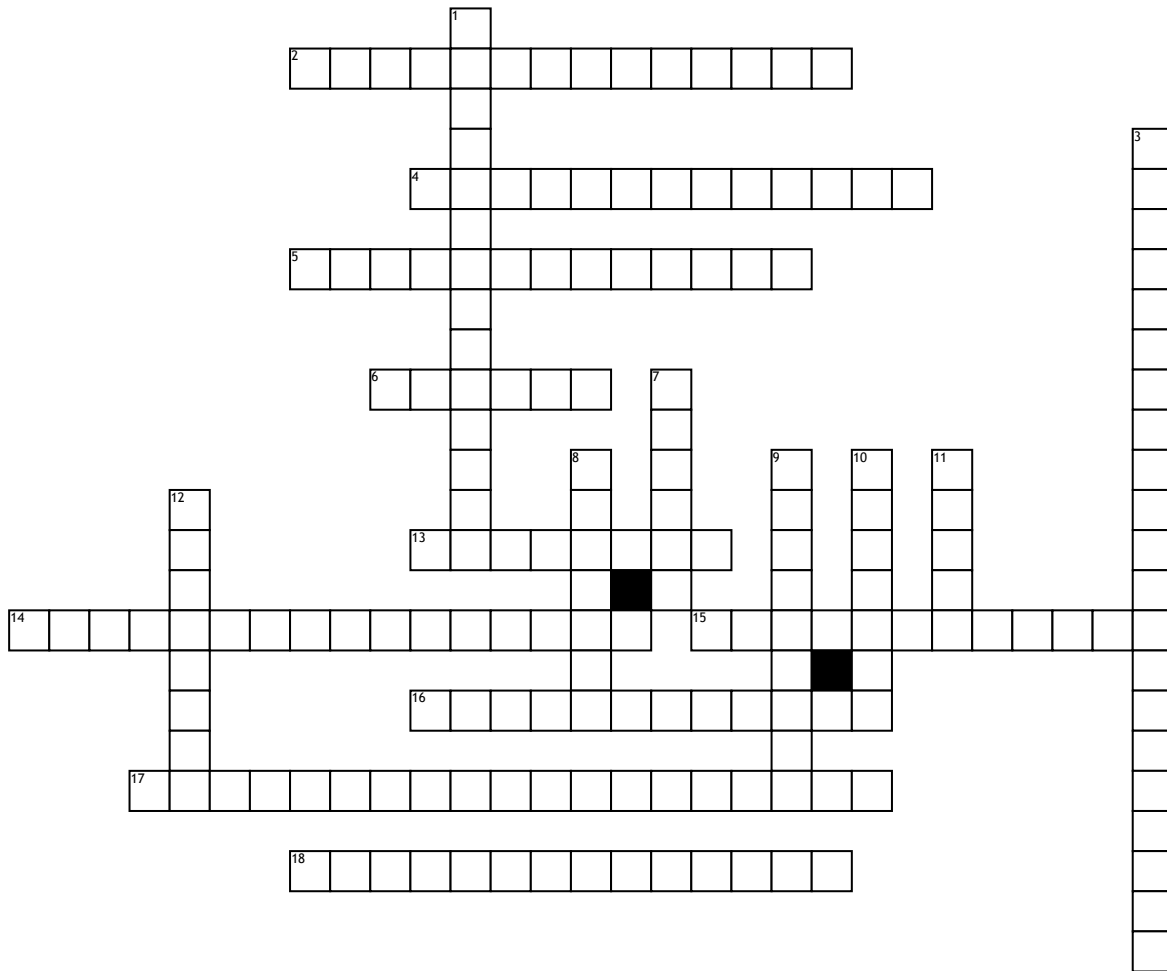


# The Lips Tell It All



## Across

- 2.** also plica fimbriata is a slight fold of the mucous membrane on the underside of the tongue which runs laterally on either side of the frenum
- 4.** / A mass of soft tissue located at the posterior end of the mandibular alveolar ridge
- 5.** A small fold of mucous membrane extending from the floor of the mouth to the
- 6.** This is the top surface of the tongue
- 13.** a specialized calcified substance covering the root of a tooth.
- 14.** A V-shaped groove, with apex pointing backward, on the surface of the tongue

- 15.** consists of plates of compact bone on the facial and lingual surfaces of the alveolar bone.
- 16.** divides the dorsum of the tongue into symmetrical halves
- 17.** a group of specialized connective tissue fibers that essentially attach a tooth to the alveolar bone within which it sits.
- 18.** interface between the sulcular epithelium and the epithelium of the oral cavity

## Down

- 1.** Cancellous bone that is located between the alveolar bone proper and the plates of cortical bone.
- 3.** located at the base of your tongue and are large and round

- 7.** space between a tooth and the surrounding gingival tissue and is lined by sulcular epithelium
- 8.** The gums
- 9.** This is the top surface of the tongue
- 10.** either of two small masses of lymphoid tissue in the throat, one on each side of the root of the tongue.
- 11.** a fleshy extension at the back of the soft palate which hangs above the throat
- 12.** Warton's duct empties saliva through these