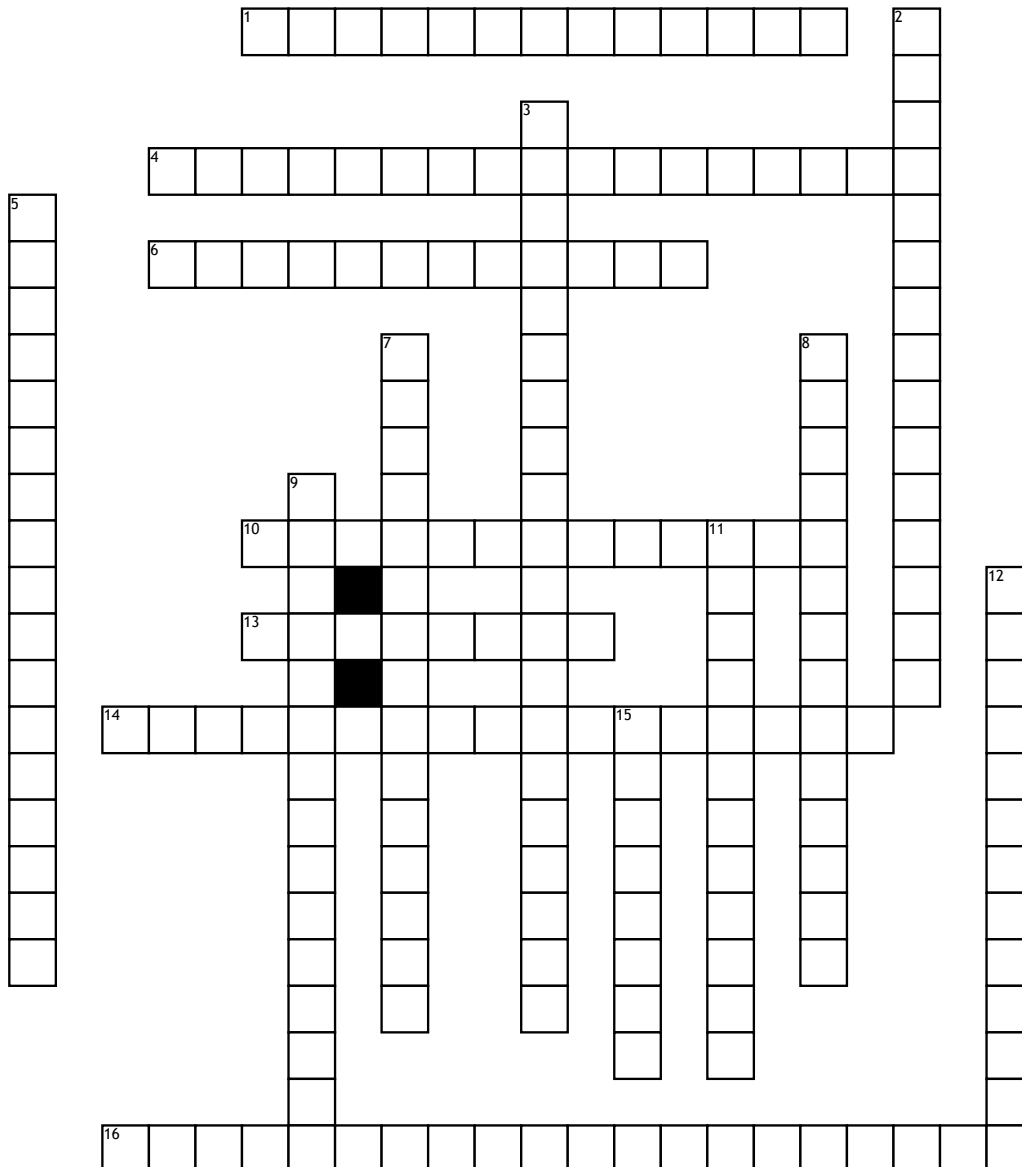


# Scapula Bony Landmarks



## Across

1. Thick edge of scapula closer to arm
4. surface of attachment for infraspinatus muscle of shoulder
6. Thin edge of scapula closer to vertebral column
10. where superior border meets the medial border
13. asdfadf
14. prominent indentation along superior border through which suprascapular nerve passes

16. region of the scapula from which the long head of the biceps brachii muscle originates. It is a small, rough projection superior to the glenoid cavity near the base of the coracoid process.

## Down

2. Projection of anterior surface at the lateral end of superior border of scapula. tendons of muscles and ligaments attach.
3. tubercle located on the lateral part of the scapula, inferior to (below) the glenoid cavity.
5. Lateral end. Surface of attachment for supraspinatus muscle of shoulder.

7. prominent bony point at the junction of the lateral border of acromion and the spine of scapula.
8. Prominent ridge that runs diagonally across posterior surface of scapula
9. slightly hollowed out area on anterior surface of scapula, has surface of attachment for subscapularis muscle
11. shallow depression that accepts head of humerus (arm bone) to form glenohumeral (shoulder joint)
12. where the medial and lateral borders join, at the bottom
15. Flattened, expanded process at the high point of the shoulder