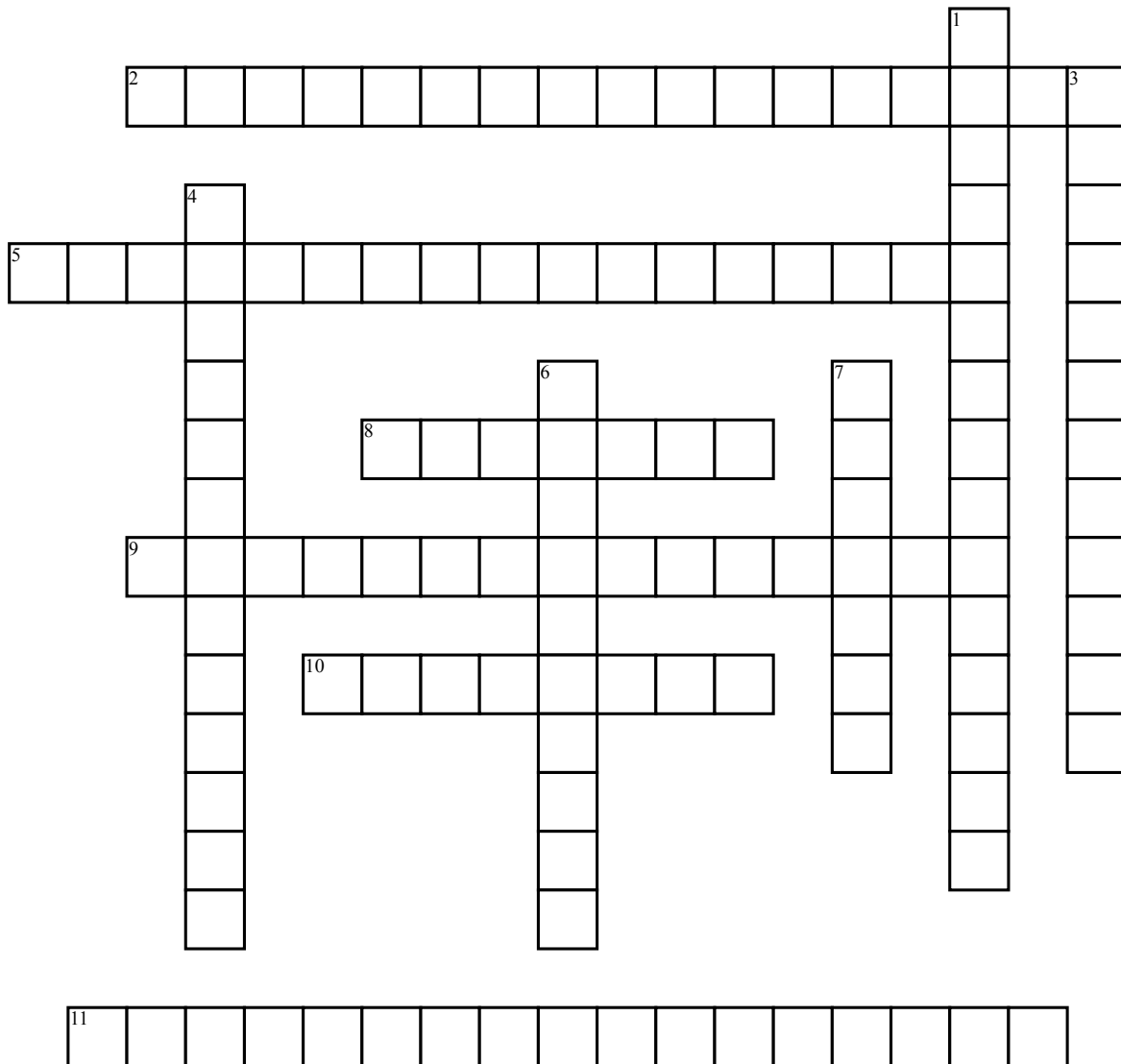


# Pelvic, Hip Joint & Gluteal Region



## Across

2. Nerve exits with the pudendal nerve
5. Where piriformis, obturator internus, obturator externus, superior and inferior gemelli attach
8. Nerve that can get compressed from piriformis syndrome
9. Nerve that innervates the gluteus medius, gluteus minimus and tensor fasciae latae
10. Ligament that forms part of the inguinal triangle

11. Ligament with a small passage for the obturator vessels

## Down

1. Nerve that innervates the gluteus maximus muscle
3. Creates the lesser and greater sciatic foramen. Attaches to ischial spine
4. Creates the lesser and greater sciatic foramen. Attaches to ischial tuberosity
6. A synovial joint of the pelvic girdle
7. Nerve that exits via greater sciatic foramen and re-enters via lesser sciatic