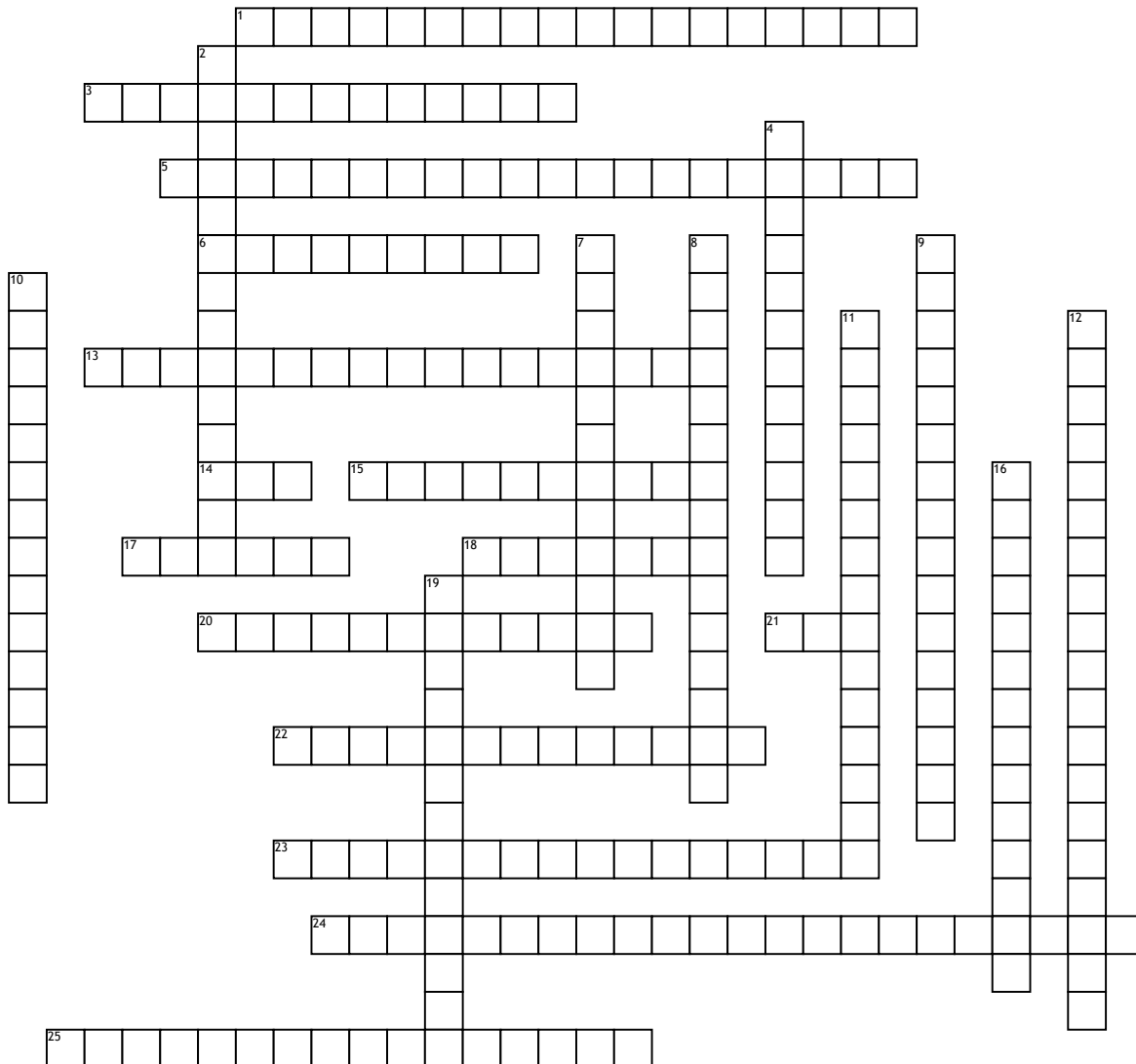


Pathology terms



Across

1. Inflamed tissue, usually associated with sun exposure
3. ??? insitu - can turn into SCC
5. Age Spot
6. a mass of granulation tissue, typically produced in response to infection, inflammation, or the presence of a foreign substance
13. Looks like BCC but is benign hair follicle tumor
14. an uncontrolled growth of abnormal cells arising in the squamous cells, which compose most of the skin's upper layers (the epidermis)
15. Benign tumour due to excess blood vessels - strawberry birthmark
17. Mole

18. Harmless bump arising from the nerve cells in the skin
20. Benign nodule
21. slow-growing and almost never spread to other parts of the body. However, if they are left untreated they can damage or destroy the skin and surrounding tissues
22. Collection of blood vessels near surface of skin
23. Rough scaly patch from years of sun exposure
24. Thickened skin resulting from repeated rubbing, scratching and itching
25. Benign funnel shaped cyst

Down

2. Spider veins
4. Harmless patch of darkened skin

7. Bumps on the skin that do not change, they resemble a flesh coloured mole
8. dome shaped lump - volcano like, superficial crater filled with keratin plug
9. Lip inflammation caused by long term sunlight exposure
10. Outer layer of skin is thickened (outer layer contains keratin which is a protective protein)
11. Unusual mole - may be removed or watched for changes
12. Bumps on the skin that do not change, they resemble a flesh coloured mole
16. Sun Spot
19. Benign tumour of the skin - due to sun exposure or therapeutic radiation