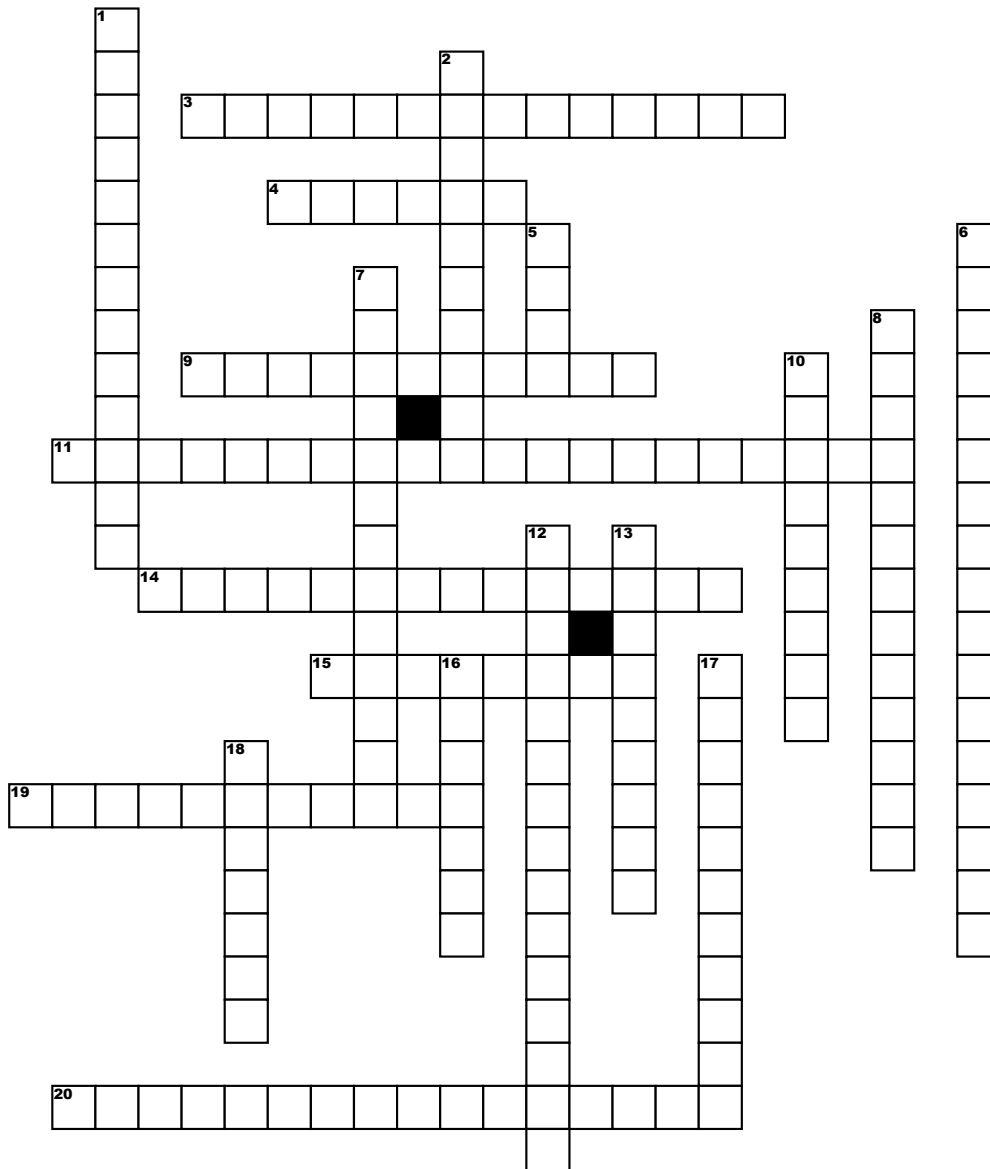


# MMC&RI Medical Crossword- WORDPLAY



## Across

**3.** It is a chronic parasitic disease caused by filarial worm, it is transmitted in humans by the bite of an insect-black fly of genus Simulium, which breeds in fast flowing rivers in tropics and subtropics.

**4.** Major site for phosphorus regulation is

**9.** A soldier presents with a penetrating leg injury. Two days later shows swelling and palpable crepitus around the injury. One of the characteristic tests showed positive by this organism is

**11.** A middle aged primigravida complains of headache, blurring of vision and swelling of lower limbs throughout the day. She also complains of tingling and numbness in palms. What is the cause for the latter?

**14.** #Oblique popliteal ligament is a continuation of which muscle

**15.** Teratogenic vitamin

**19.** It is an alkaloid of periwinkle plant, inhibits microtubule formation, one of the side effects is SIADH (Syndrome of Inappropriate secretion of ADH)

**20.** Muscle with 8 digitations, also called 'boxer's muscle'.

## Down

**1.** #Ebner's glands secrete

**2.** #Histopathological slide shows Reed-Sternberg cells, the fever associated with this condition is

**5.** The neurotransmitter in the tract from striatum to substantia nigra is

**6.** I look like a boot in a cage, I bother you at a very young age.

**7.** A term for elements of crime, it includes body of the victim and other facts which are conclusive of death by foul play.

**8.** #The ultrasound finding of a detached endocyst floating within the cavity of a hydatid cyst is

**10.** The nerve which has the longest intracranial course is

**12.** #Site of lesion causing short term memory loss in Wernicke's encephalopathy

**13.** An electrolyte which when in low level causes flat T wave and when in high level causes flat P wave in ECG.

**16.** A good homicidal poison, lasts long in bones, mimics an epidemic diarrhoea.

**17.** A child presents with abdominal mass, with history of hematuria and abdominal pain. It has microscopic features of triphasic tumour (blastemal, epithelial and stromal components). What's the diagnosis?

**18.** Smallest alkali ion, used as a mood stabilizer, has narrow therapeutic index