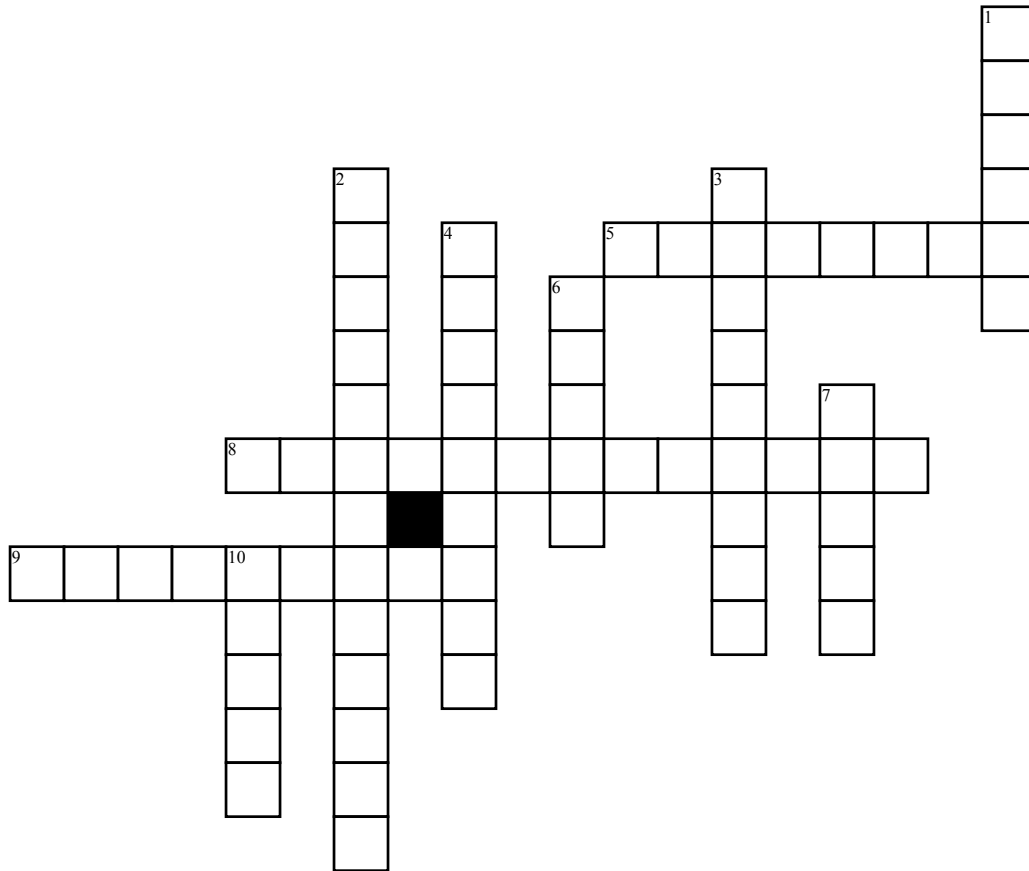


Name: \_\_\_\_\_

# Joint



## Across

5. The \_\_\_\_\_ is a ball-and-socket joint and includes the scapula and humerus
8. Temporary joint in which bones are united by bands of hyaline cartilage
9. Fibrocartilage fills slightly movable joint

## Down

1. Immovable joint between flat bones of the skull

2. Movement in all planes

3. Joint formed by union of tooth root in bony socket

4. This cartilaginous joint can be found in the pubic symphysis or in the intervertebral discs

6. This joint allows for sliding and twisting

7. This synovial joint allows for rotation

10. The elbow (humerus and ulna) is a \_\_\_\_\_ joint.

## Word Bank

Ball-and-socket

Symphysis

Suture

Symphysis

Hinge

Plane

Shoulder

Gomphosis

Symphysis

Pivot