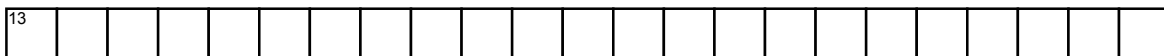



DERMATOLOGY QUIZ



Across

- 4. A VARIANT OF PYODERMA GANGRENOSUM WHICH OCCURS DURING PREGNANCY IN THE GINGIVA
- 5. TRIAD OF CUTANEOUS ERYTHEMA, LYMPHADENOPATHY AND 10-15% ATYPICAL MONONUCLEAR CELLS
- 11. ANGIOSARCOMA ASSOCIATED WITH CHRONIC LYMPHEDEMA MOST COMMONLY OCCURRING IN THE UPPER EXTREMITIES FOLLOWING MASTECTOMY
- 12. CHARACTERISTIC OF AN AUTOIMMUNE DISORDER SEEN AS REDDISH PURPLE ERYTHEMA INVOLVING THE FACE AND EYELIDS
- 13. A PLATELET TRAPPING CONSUMPTION COAGULOPATHY ASSOCIATED WITH VASCULAR TUMOR

Down

- 1. BLUE BLACK HYPERKERATOTIC PAPULES A FORM OF ANGIOKERATOMA OF THE SCROTUM:
- 2. BENIGN ACQUIRED VASCULAR DISEASE INITIALLY CONFUSED WITH KAPOSI SARCOMA
- 3. A SYNDROME ALSO KNOWN AS BLUE PSORIASIS ASSOCIATED WITH SCC OF THE UPPER AEORODIGESTIVE TRACT
- 6. A SYNDROME CHARACTERISED BY MULTIPLE MAT LIKE TELENGIECTASIAS SEEN ON THE FACE, LIPS, TONGUE, EAR, HANDS AND FEET ASSOCIATED WITH INTERNAL BLEEDING

- 7. SIGN WHERE THERE IS RECURRENT AND MIGRATORY SUPERFICIAL THROMBOPHLEBITIS AFFECTING BOTH THE LARGE AND SMALL CUTANEOUS VEINS ASSOCIATED WITH PANCREATIC CANCER: Trousseau
- 8. A SIGN SEEN IN DERMATOFIBROMA
- 9. A TUMOR WHICH IS AN UNCOMMON PIGMENTED VARIANT OF DERMATOFIBROMA SARCOMA
- 10. A SYNDROME WHICH INCLUDES SEBACEOUS NEOPLASIA AND HIGH INCIDENCE OF LOW GRADE COLON CANCER