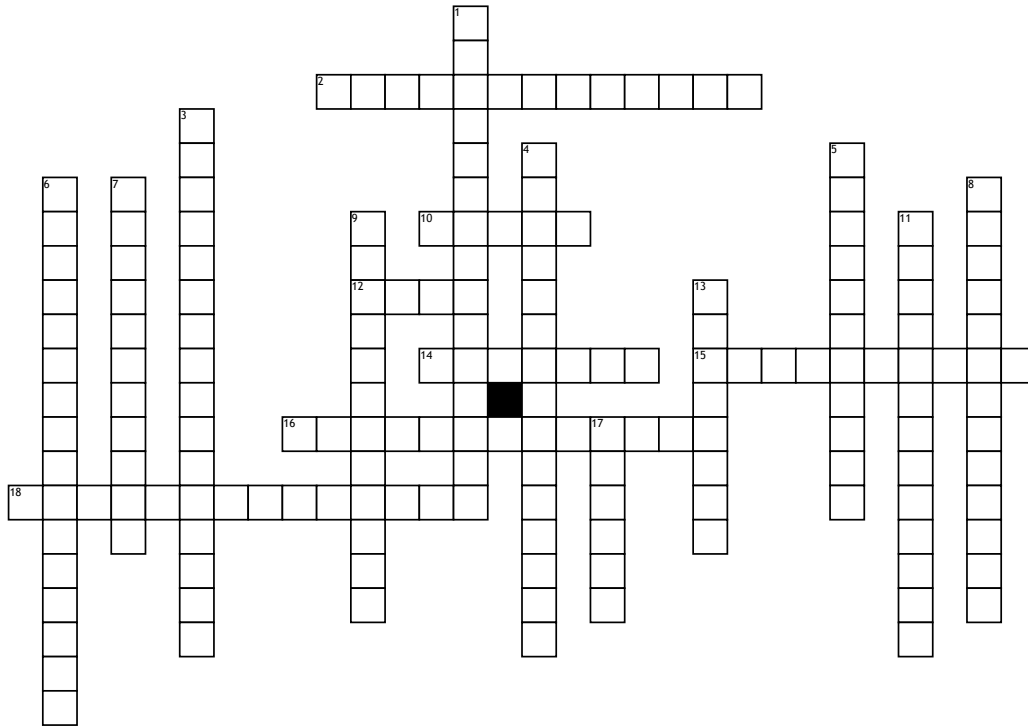


# Chapter 12 & 13



## Across

2. Dura mater consists of two layers, the inner layer is known as?

10. The outer cortex of the cerebellum contains what?

12. Convolutions of the cerebrum separated by sulci (plural).

14. Both vertebral arteries come together to form this artery.

15. The cerebellum internally presents white matter branching in the form of a tree called?

16. Another name for the endocranium or endosteum.

18. A sinus found lateral to the sella turcica on each side.

## Down

1. A particular arrangement of veins in which two veins lie on either side of the artery and have the same name as the artery.

3. Part of the brain that is directly continuous with the spinal cord.

4. Innervation of the scalp anterior to the external ears is through which nerve?

5. Separates the superior portion of the right and left sides of the cerebrum.

6. A fold that is small, circular, and is pierced by the infundibulum?

7. Layer 4 of the scalp is also known as?

8. Separates the pre-central and post-central gyri.

9. This dural sinus has a distinct S shape and extends from the transverse sinus.

11. Found between the junction of the falx cerebri and the tentorium cerebelli.

13. The most important sensory relay center of the brain.

17. The cranial bone layer of the skull that is made up of spongy bone.

## Word Bank

Cavernous Sinus

Medulla Oblongata

Meningeal Dura

Folia

Arbor Vitae

Falx Cerebri

Basilar

Sigmoid Sinus

Straight Sinus

Diaphragma Sellae

Venae Comitantes

Gyri

Danger Layer

Trigeminal Nerve

Diploe

Thalamus

Central Sulcus

Endosteal Dura