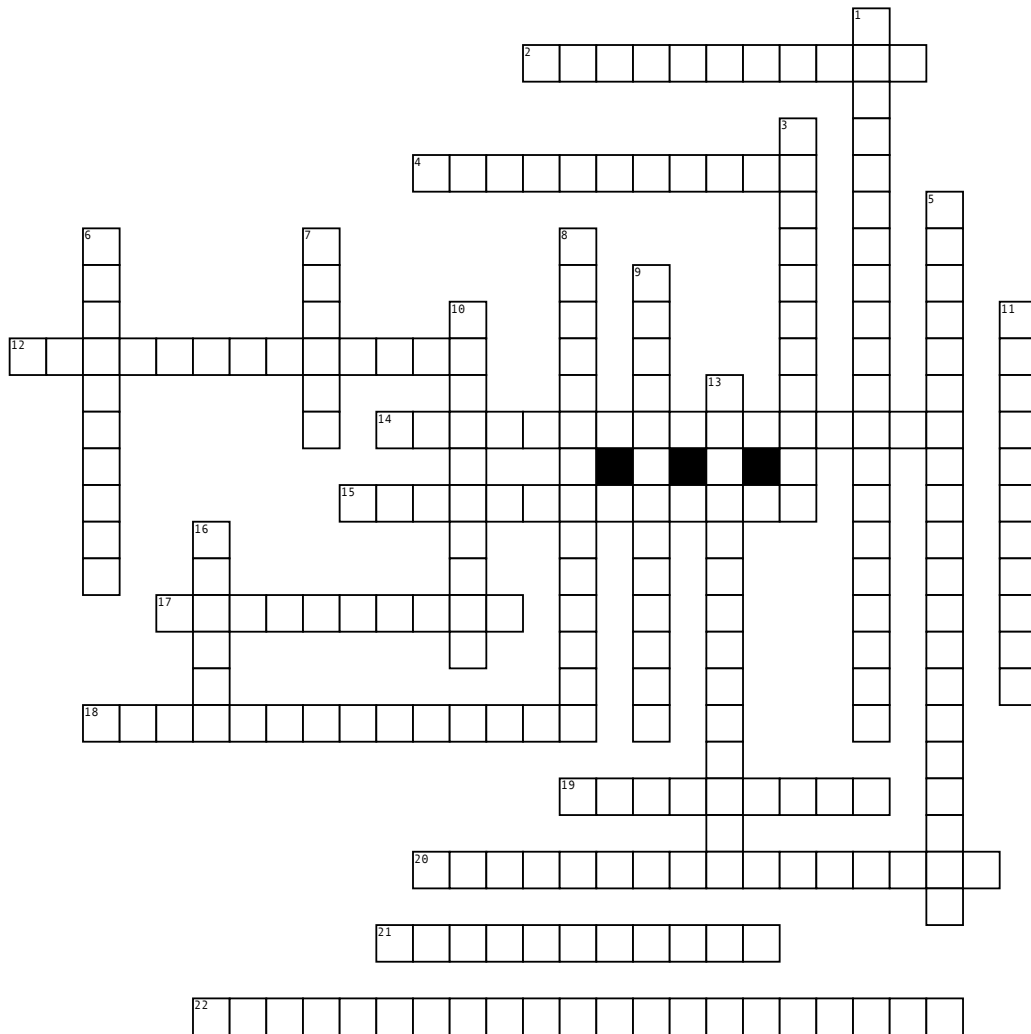


# Cardiovascular System



**Across**

- 2. top part of the septum
- 4. located between left ventricle and aorta
- 12. opening between left atrium and left ventricle
- 14. bottom part of the septum
- 15. receives blood from the left atrium, pumps oxygenated blood to the rest of the body, strongest chamber
- 17. Thin, outermost layer. Joins with lining outside the heart to form the Pericardium
- 18. opening between right ventricle and pulmonary artery

- 19. Another name for the pulmonary valve
- 20. threads, keep valve flaps from flipping up into the atria
- 21. Smooth layer, Lines the interior, and valves are made from this layer
- 22. Another name for tricuspid valve

**Down**

- 1. It is also known as the "transportation" system of the body
- 3. needs blood supply, blood supplied through the right and left coronary arteries
- 5. Another name for the Bicuspid/Mitral valve
- 6. Muscle layer and Thickest layer

- 7. Are important to control the flow of blood from one chamber of the heart to another and allows blood to flow in only one direction
- 8. receives blood from the right atrium, pumps blood to the lungs
- 9. collects venous blood from the heart and empties into the right atrium
- 10. receives oxygenated blood from the pulmonary veins
- 11. receives blood from the superior and inferior vena cava
- 13. opening between right atria and right ventricle
- 16. Separates the left and right heart

**Word Bank**

- |                       |                       |                        |                   |
|-----------------------|-----------------------|------------------------|-------------------|
| Valves                | Left Atrium           | semilunar              | Interventricular  |
| left atrioventricular | Coronary Sinus        | Pulmonary valve        | Chordae Tendineae |
| Right Ventricle       | Left Ventricle        | Septum                 | Myocardium        |
| Interatrial           | Cardiovascular System | right atrioventricular | Bicuspid Valve    |
| Tricuspid Valve       | Heart Muscle          | Right Atrium           | Epicardium        |
| Endocardium           | Aortic Valve          |                        |                   |