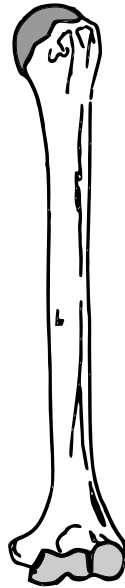


Bones of the Skeleton



metatarsals
metacarpals
occipital
zygomatic
vertebrae
phalanges
sphenoid
palatine
parietal
temporal
mandible
clavicle
maxilla

Z V T S L A P R A C A T E M L Z E K F N Y C I V
 U S S Z Y G O M A T I C X V U G Z X B D X Z H G
 S K L N P I K U S C A P U L A N E I S W E E L Y
 U G A K A M H F M R I P S H U J R T M U R C A S
 R S T F P S S X V A W J Z Q Z E D E H N E G V S
 E Z E L J H A N Q L I I P D U L Y V T M G G M F
 M F I H S G Z L S L G D A R P V B V Y S O Q O R
 U D R D Y L F F O I L R T Q V Z K W J X Z I U Y
 H I A T T H A Z J X J A G S L A S R A T B M D R
 Q O P W X T Y P M A O L T W A C E V V O E L P A
 N N C M Z I Z O R M G O D N G M X L Q F C H I D
 Y E G O T B J F I A E P N E O Y S A L T A E W I
 T H G A E I T C J D C M U N R R Q A A L L L Q U
 L P S P M A A Q M U I L I B L U F G A C Q N S S
 D S S Z P A C U O G V R Q J I H B N I K M I A K
 L K C L O W L Z K G A X K S Y S G V S G N X M E
 B K P Y R N L A Q A S I B Z J E A I K S I U T A
 X X E P A G A Z A T X D W C S L T L B S I B U R
 Z Y L H L O X W L O P Z J I C Q I S C H I U M B
 B Y C V A B O J U O C C I P I T A L D G M Y G E
 C T H C Y M C C B M E T A T A R S A L S I H F T
 U R H W O Y O F I Z P A L A T I N E H Q E P K R
 M M A V O C Z U F M T G M H E L B I D N A M Z E
 Q B V S S D U N Z I L B L X V K R E J Y P K L V

ischium
scapula
ethmoid
frontal
truerib
humerus
tarsals
carpals
sternum
coccyx
sacrum
fibula
radius
pubis
ilium
hyoid
atlas
coxal
nasal
tibia
femur
axis
ulna