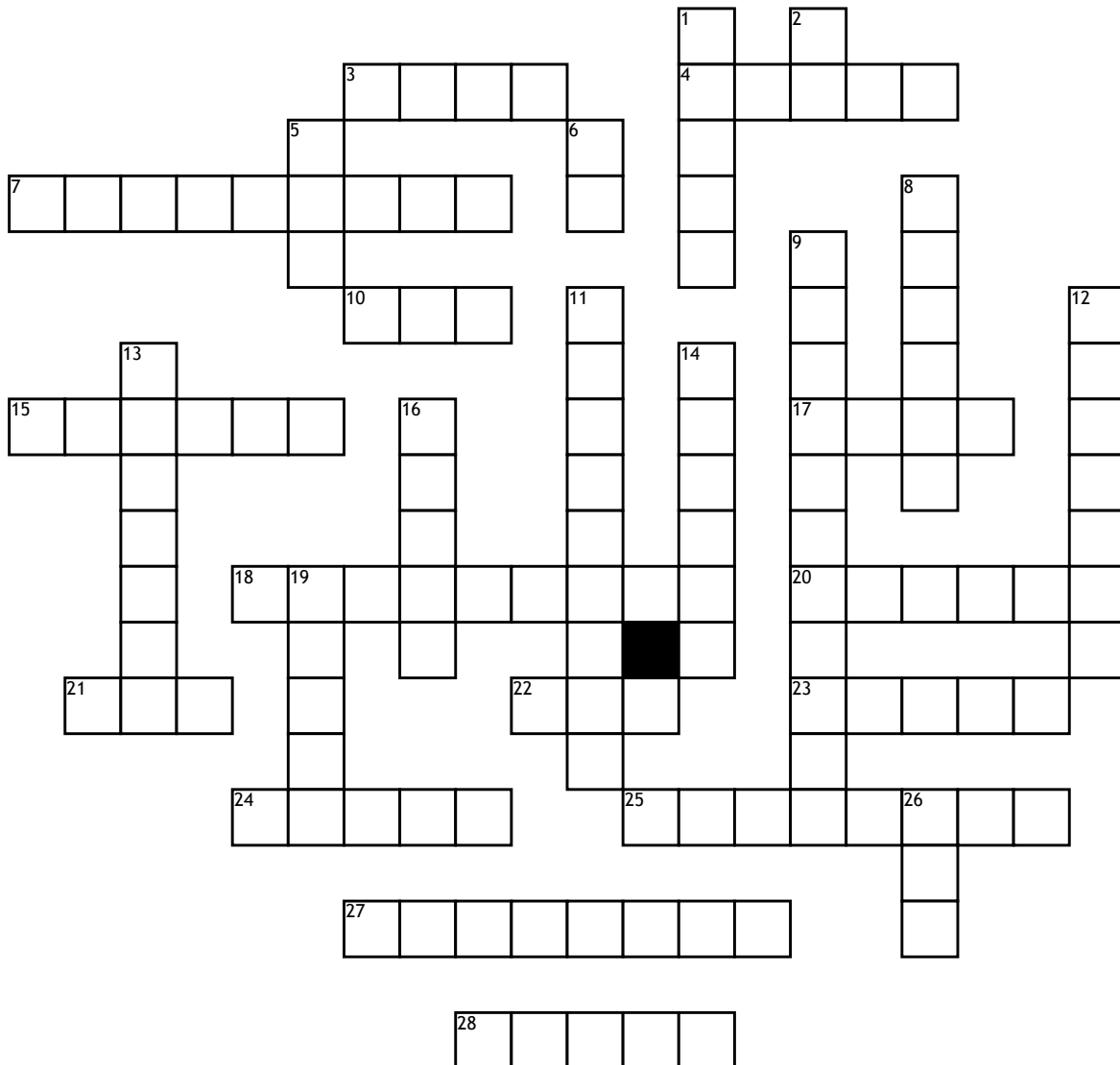


Name: _____

Date: _____

Body Structure



Across

- 3. tail
- 4. separation
- 7. study of tissues
- 10. Magnetic resonance imaging
- 15. surgical repair
- 17. inflammation
- 18. middle region located near the navel
- 20. formation or growth
- 21. lateral
- 22. above, on
- 23. anterior, front
- 24. through , across

- 25. band of scar tissue

- 27. towards the head

- 28. the same

Down

- 1. pain
- 2. ultrasound
- 5. left lower quadrant
- 6. biopsy
- 8. neck; cervix uteri
- 9. verticle plane that passess through the midline of the body and divides the body left and right

- 11. visual examination of the interior of ortans and cav ity with a specialized lighted instrument

- 12. pertaining to the skull

- 13. softening

- 14. enlargement

- 16. Poison

- 19. instrument used to measure

- 26. ilium (lateral, flaring portion of the hip bone)