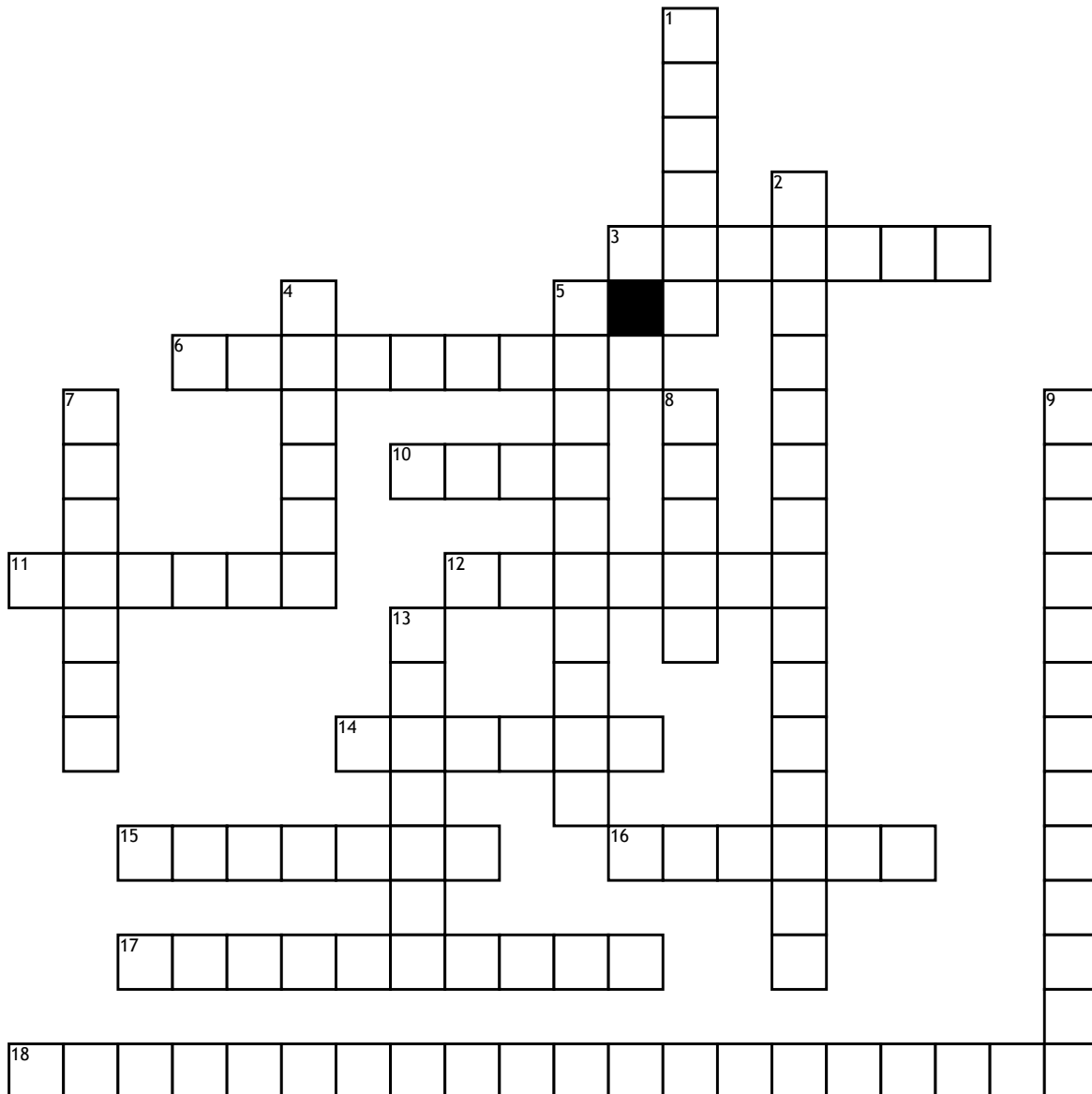


Axial & Appendicular Skeleton



Across

3. upper bone that connects scapula to the elbow

6. toes

10. runs to the point of the elbow and accepts the end of the humerus

11. made of two halves and divides into regions (ilium, ischium, pub)

12. flat bone with a spine to attach tendons and ligaments

14. group of bones arranged into two rows

15. flat bones that varies between species and breeds

16. A lower-leg bone that extends from the knee to the outside of the ankle

17. long bones dogs and cats have four with a smaller one (dewclaw)

18. these bones allow for movement

1. closely connects to the ulna forming the rest of the elbow joint

2. protects the spinal cord and is broken down into 5 anatomical

4. ankle

5. top of the foot

7. kneecap

8. ball and socket joint to the pelvis that goes to the knee

9. used to protect fragile tissue that is held underneath

13. joins the humerus through a shallow ball and socket joint