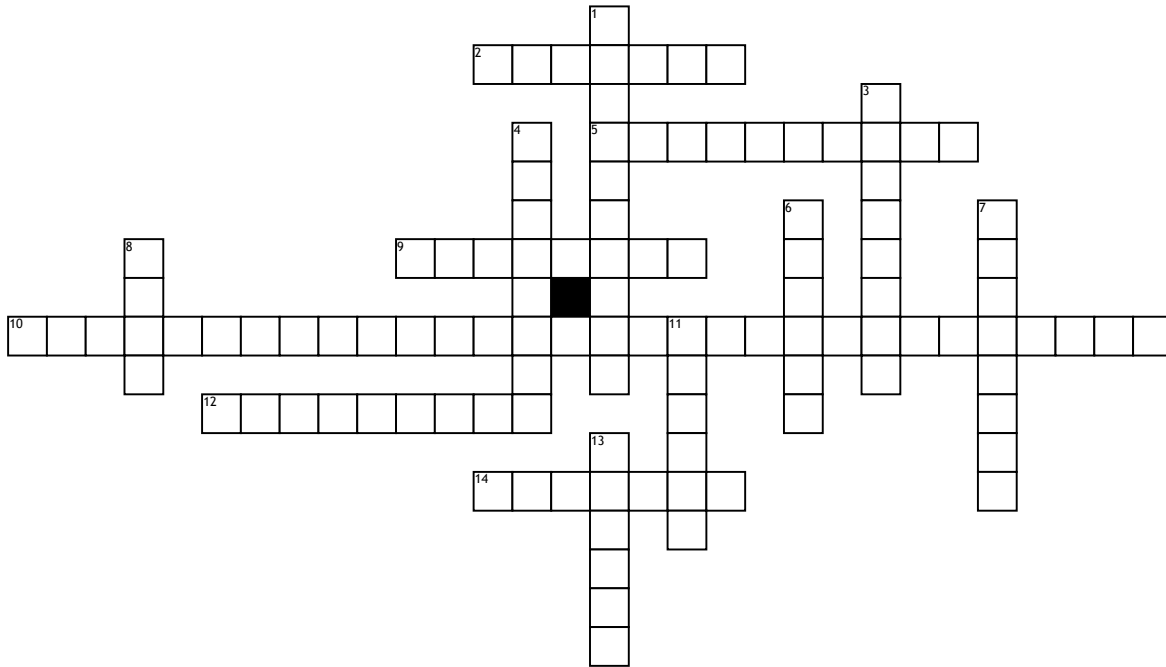


Anatomy



Across

2. When the body is divided longitudinally dividing it into the anterior and posterior aspects it is called the _____ plane.
5. If a cross-section divides the body into upper and lower parts it is called a _____ plane.
9. The neck is _____ to the toes.
10. What are the four body cavities from the superior to the inferior part of the body?

12. The vertebrae is dorsal/ _____ to the sternum.

14. The humerus is _____ to the lungs.

Down

1. What do we call the position of the body in Figure 1.18? The _____ position.
3. The femur is _____ to the fibula.
4. The nose is on the ventral/ _____ aspect of the body.
6. The lungs are _____ to the humerus.

7. The toes are _____ to the neck.

8. How many regions do we divide the abdomen in?

11. The fibula is _____ to the femur.

13. When the body is divided longitudinally through the midline into right and left halves, it is called the _____ plane.