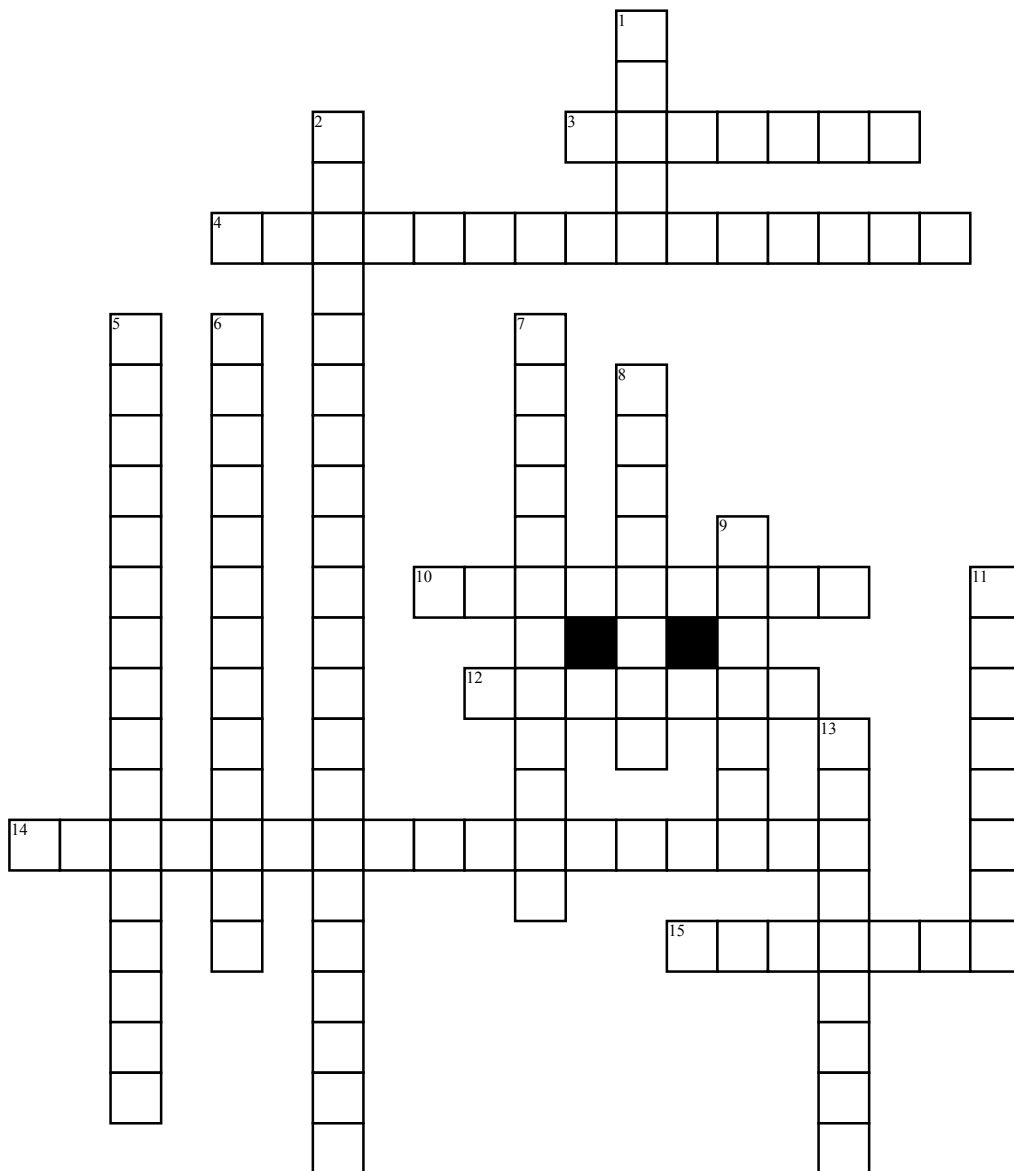


# Anatomy/Views Review Crossword Puzzle



## Across

3. Another name for the AP bilateral frog-leg projection is the modified \_\_\_\_\_ method.
4. Which elbow view shows the radial head free of superimposition?
10. What is the name of the largest tarsal bone?
12. The part of the vertebra extending posteriorly from the body is called the \_\_\_\_\_?
14. The \_\_\_\_\_ is a commonly used landmark located at C7.

15. Grasheys are performed to demonstrate the \_\_\_\_\_ cavity.

## Down

1. The \_\_\_\_\_ method is done to demonstrate any injuries to the ulnar collateral ligament.
2. The Fisk modification is performed to demonstrate which bone feature?
5. What is the medial end of the clavicle called?
6. The \_\_\_\_\_ joint is located between the superior and inferior articular processes of cervical vertebrae.

7. Which acetabulum view requires a 12 degree cephalic angle?

8. There are 12 total \_\_\_\_\_ vertebrae.
9. Which (knee) tunnel view requires 40-45 degree knee flexion and a roughly 40 degree cephalic tube angle?
11. The most commonly fractured carpal bone is called the \_\_\_\_\_.
13. The PA weight-bearing knee projection is called the \_\_\_\_\_ method.