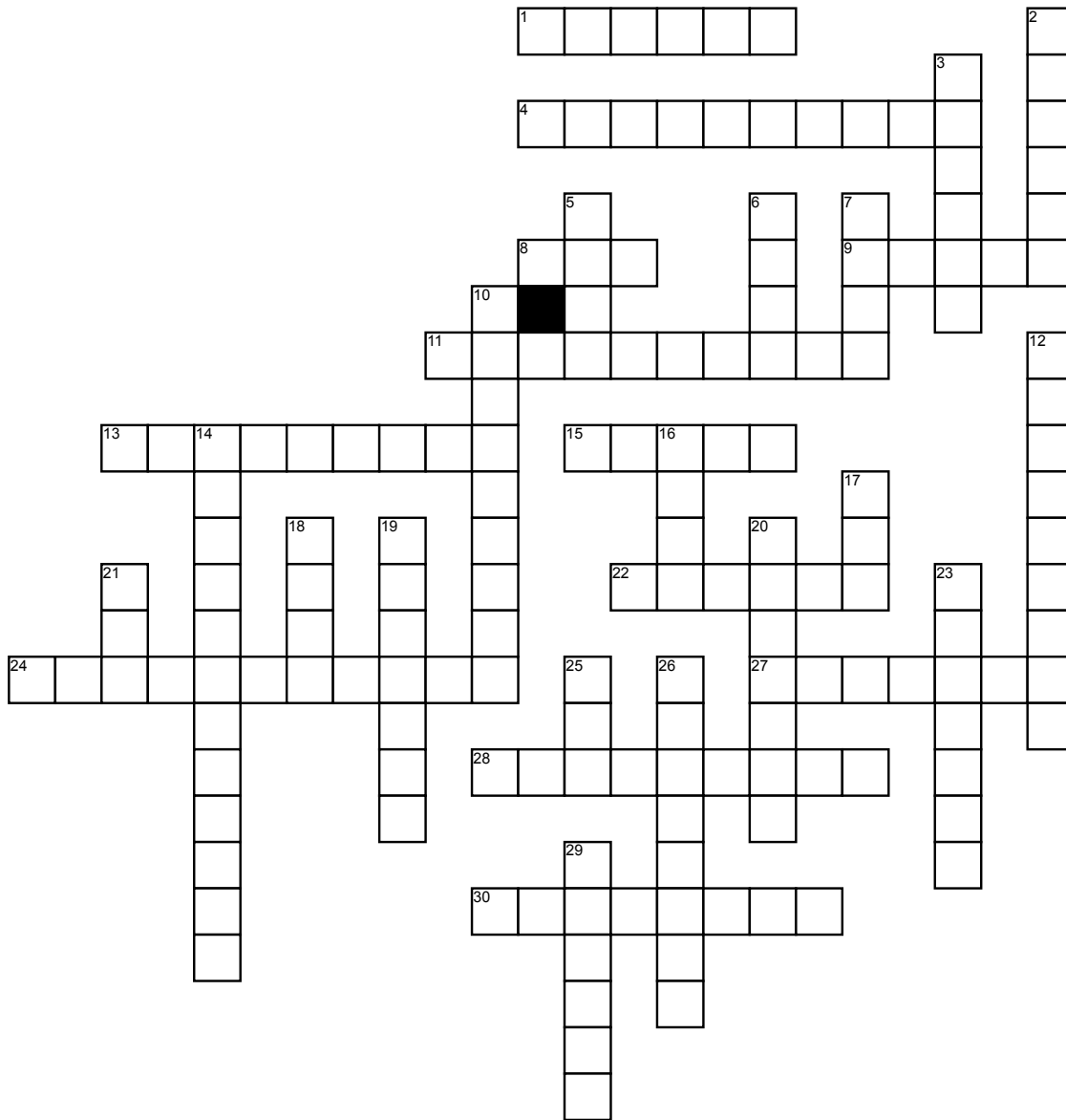


Name: _____

ASRT 1



Across

- 1. Big toe
- 4. Ultrasound probe
- 8. 2000 lbs.
- 9. Positioning guide: _____
Base Line
- 11. _____ units used in CT to
express CT numbers
- 13. Technetium TC 99M

- 15. Radiation emitted from Cobalt 60
- 22. _____ view visualizes the
maxillary sinuses
- 24. Vascular visualization via CT

- 27. _____ flexure of the colon

- 28. The "master" endocrine gland
 - 30. 1st segment of the small intestine
- ## **Down**
- 2. Common wrist fracture
 - 3. _____ caudal view in
mammography
 - 5. Worn in a sterile environment
 - 6. _____ guide, the
radiation-producing component in a
linear accelerator
 - 7. Accessory used to absorb
scattered radiation
 - 10. Rad. Therapy specialty designing
treatment plans
 - 12. Magnetic _____ Imaging
 - 14. _____ breast biopsy

- 16. _____ scan, nuclear medicine
angiocardiology
- 17. Distress signal
- 18. Number of chambers in the heart
- 19. _____ ultrasound used to
estimate blood flow
- 20. Opposite of caudad
- 21. _____ 18, radionuclide used in
PET imaging
- 23. Anode's counterpart
- 25. _____ CT, often used in cancer
staging
- 26. View sometimes employed
radiograph lateral upper T spine
- 29. Wilhelm _____ Rontgen